



Treatment Of Syndesmotic Injuries With Flexible Fixation

Cristian Ortiz, MD
Clinica U de Los Andes



Fig: GMReis Expert Knotless Dual – flexible fixation for syndesmosis.

Syndesmosis injuries may be acute and chronic. They may present as an isolated injury or most commonly, associated with an ankle fracture. Ankle fracture is the most frequently operated injury by an orthopedic surgeon and has recently received more attention related to increased awareness of potential long term complications, such as malunion and arthritis.

One of the most common malunion has been demonstrated by post op CT scans at the syndesmosis area. Failure to achieve anatomical reduction has been directly related to poor clinical outcome. Some authors show more than 50% of malrotation ($>5^\circ$) and anterior or posterior translation ($>2\text{mm}$) should be considered mal reduction.

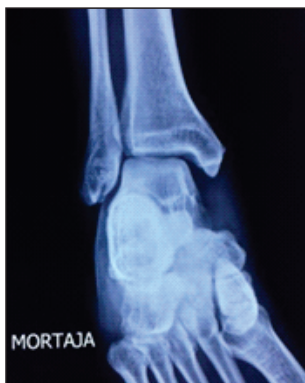

Fig.: Mortise view of the ankle showing medial and syndesmotic injury.

Clinical discussion has concentrated in some controversial aspects:

1 - How to make the diagnosis of syndesmosis injury:

Diagnosis can be quite obvious in preop weight bearing X-rays showing less than 1 mm tibiofibular overlap. It is useful to have comparative contralateral X-rays because there may be subtle changes easier to identify comparing with the uninjured side.

In case of doubt you may ask for stress X-rays or just a simple AP ankle view with lateral stress (the foot hanging at the edge of the table). MRI may be useful for ligamentous injuries as well as for associated injuries.

Weight bearing CT scan is useful to detect mild asymmetric changes when comparing with the contralateral side, but unfortunately is not worldwide available.

Intraoperatively syndesmosis should be tested aggressively looking for instability using any instrument strong enough to

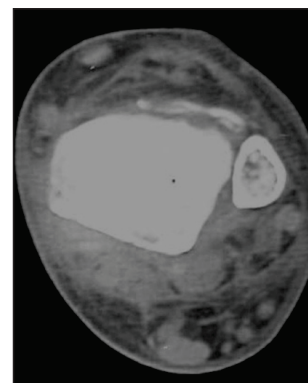
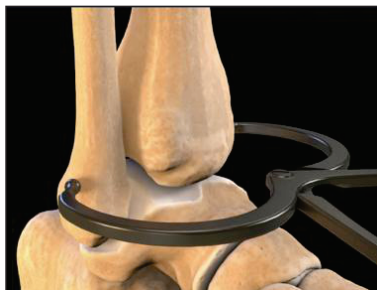
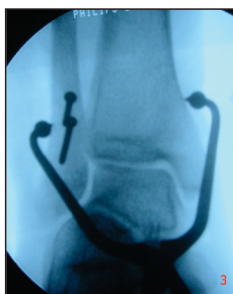
Fig.: Anterior translation of the fibula in syndesmotic injury.

2 - How to achieve anatomical reduction:

Since anatomical reduction is mandatory for good clinical results, it is recommended to be extremely accurate to obtain reduction easily and hopefully without the need of a strong clamp. If the clamp is needed it should reduce the syndesmosis with mild pressure. It is even better if the gap closes by itself and you hold the tibia and fibula together with one hand. If the fibula and the posterior malleolus are anatomically reduced it typically comes into its position easily. If not, it is recommended to revise length and rotation of the fibula as well as the perfect reduction of the posterior malleolus.





Figs.: GMReis Clamp to secure fixation before reduction.

3 - How to fix the syndesmosis:

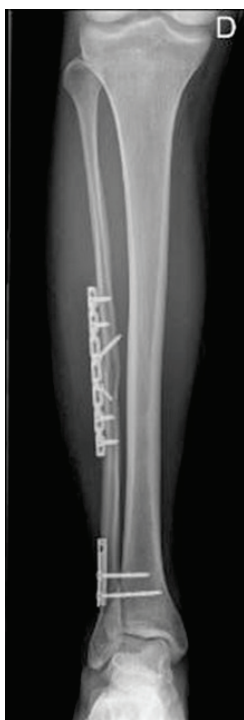

Fig.: X-ray demonstration anatomical fixation of the fibula and syndesmotis reduction with two screws.

Where to put fixation:

Syndesmosis fixation is recommended to be just above the syndesmosis. This is why in the literature you will generally read: between 2 to 4 centimeters over the ankle joint line. If fixation is at the level of the syndesmosis, the likelihood of stiffness and ossification is theoretically increased.

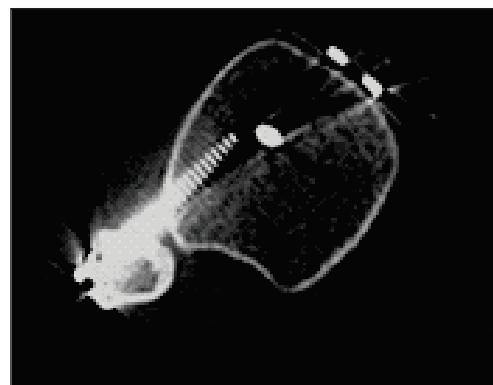


Fig.: CT scan showing malreduction of syndesmosis with a screw.

If screw are used, should they be removed?

It was initially recommended to remove screws between 6 to 8 weeks, but evidence came up showing increased failure with reopening of the syndesmosis. It was then recommended not to remove screws before 3 to 5 months but at that moment of the recovery most patients had a progressive recovery and did not want to go back for surgery. X-rays typically shows that the screw is broken at the syndesmosis level or a windshield effect was observed at the tibia. This means that the syndesmosis recovered at least part of its motion by itself. We have occasionally seen patients that around 4 months after surgery they may experience permanent restriction of dorsiflexion that seem to go away when the screw loosens or it may need to be removed.

Rigid or flexible fixation:

Flexible fixation is one of the most innovative advances to fix syndesmosis injuries. To have a method of fixation that does not provide rigidity but is stable at the same time and does not need to be removed is very appealing.

Over the years several studies have shown that this type of fixation is at least as stable as a screw in biomechanical studies.

In clinical trials it does not have more failures than rigid fixation and interestingly is has shown that anatomical reduction is more likely to be achieved and patients seem to feel better.

These findings make sense if you think that flexible fixation brings fibula into the incisura fibularis of the tibia smoothly, decreasing the risk of malrotation and translation commonly seen in post op CT scans after screw fixation. Since this type of fixation maintains at least part of the physiological motion of the joint it may explain why patients feel better and seem to recover sooner. The knotless fixation is not prominent so removal is unlikely to be needed.




Fig.: GMReis Expert Knotless Flexible Fixation.

Should every fibular fracture be fixed before syndesmosis reduction

Although, in order to obtain anatomical reduction, some authors fix even the more proximal fibular fractures, this is technically demanding and may increase soft tissue damage as well as neuropaxia of the fibular nerve.

Since anatomical reduction of the length and rotation of the fibula is paramount, most surgeons recommend to fix fractures that are all the way up to half of the length of the fibula.

If fracture is more proximal than this, traction with a clamp and reduction of fibular length and rotation may be necessary.

When should I use more than one fixation:

There is just poor level of evidence to answer this question but most surgeons would recommend to use two flexible fixations if: patient is heavy, an athlete or there is significant instability. This is typically the case for proximal fractures and also when post-ant instability of the fibula is evident while reducing and fixing the fracture.

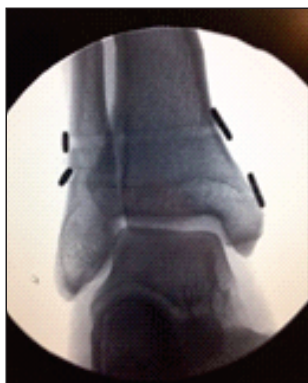

Fig.: X-ray showing two flexible fixation of the syndesmosis.

Can fixation be isolated without a plate:

Again, there is not solid evidence, but since fibular and even tibial fractures have seen when and isolated flexible fixation has been used most author would add a plate in osteoporosis and when using double fixation (for severe instability as discussed in the previously).

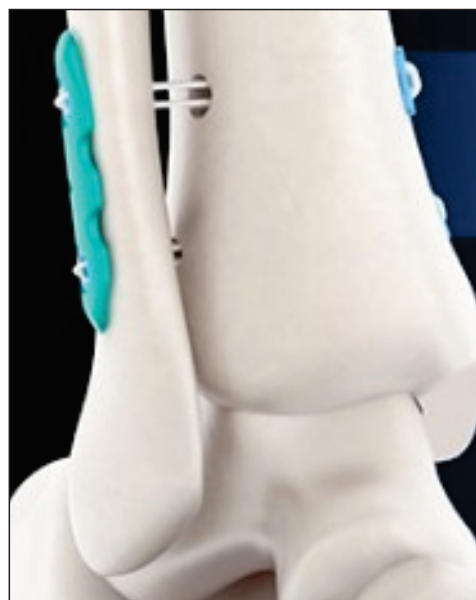

Fig.: 3d model shows preferred option when using two flexible fixations.

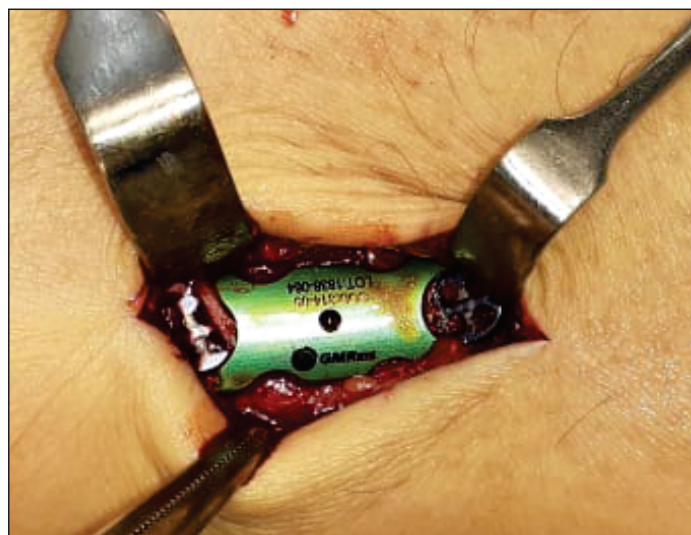

Fig.: GMReis Expert Knotless Dual - plate with double flexible fixation (intraoperative picture).

Repair AITFL?

This consideration has recently been suggested when performing open reduction and fixation of the fibula; and there is significant instability this may be controlled repairing the ATFL. Since a simple suture would probably not be strong enough, a tape with knotless anchors in its isometric position is an easy way to solve the problem.

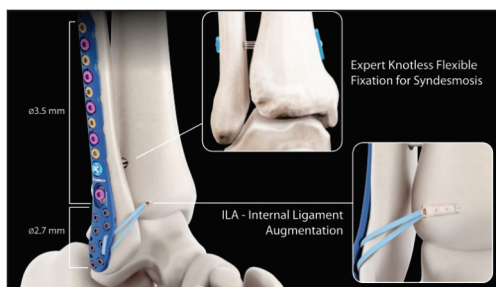


Fig.: GMReis products can be used combined for treatment of fibular fracture, syndesmosis injury and augmentation of AITFL repair, using Versalock Distal Tibia Anatomic Plate, Expert Knotless and Fastlock knotless tape loaded anchor.

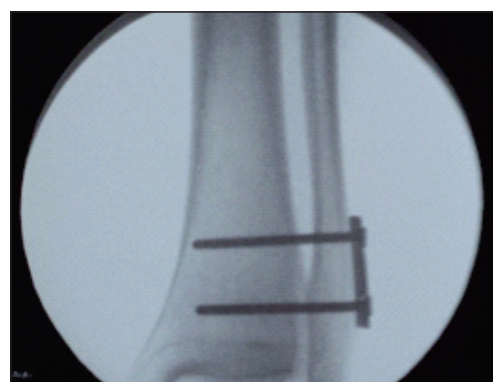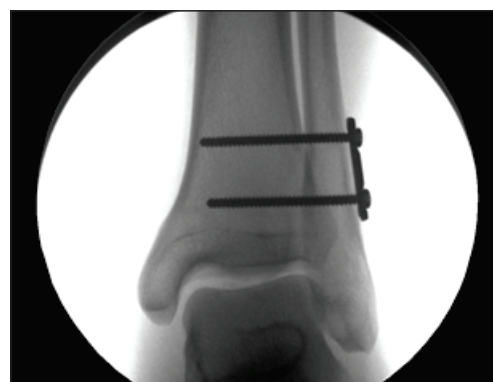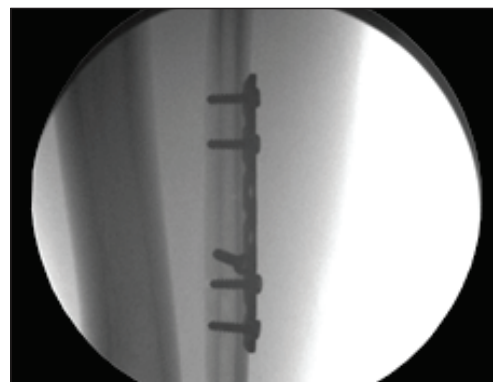
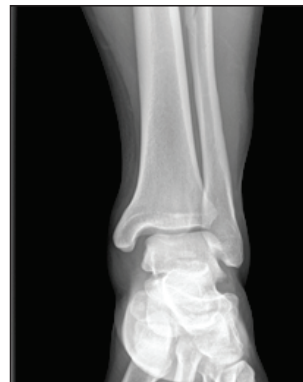4 - Timing during surgery (fibula, posterior malleolus and medial deltoid injury):

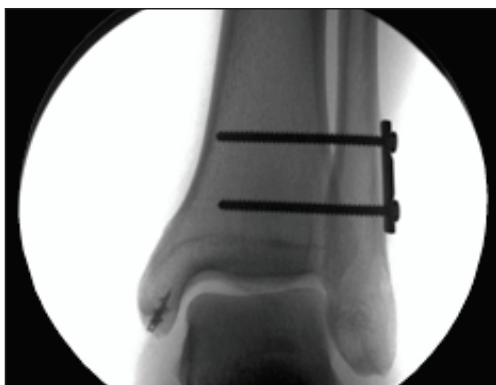In case of the most classical bimalleolar ankle fracture (fibula and medial malleolus), it is easy to fix the fibula, then the medial malleolus and finally test and fix the syndesmosis.

If fibula is too comminuted some authors would prefer to fix the less comminuted bone first to achieve reduction.

This is exactly the case for the posterior malleolus that is recommended to fix in the first place and the fibula and medial malleolus. Done this way and if the posterior syndesmotic ligaments are intact, the syndesmosis may be stable and not need reduction or fixation.

When there is a bimalleolar equivalent fracture (with complete deltoid ligament rupture) some have seen that if ligament is repair, syndesmosis may recover its stability. But since most of deltoid repairs just achieve part of the superficial portion of the ligament we prefer to go the other way around. That means fixing the syndesmosis and if the medial side persists to be unstable then we would proceed with medial repair.





Figs.: Show a high syndesmosis injury that after being fixed, medial instability was observed and deltoid repair was needed.




Fig.: GMReis Expert Knotless Dual – all components are supplied in a single sterile package.

5 - Post op protocol:

This has evolved from a very strict 6 weeks in a non weightbearing cast into a more functional rehabilitation. Anyway, most surgeons would still prefer at least 3 weeks non weightbearing in a removable boot. In our experience the compliant patient seems to control him self so we allow them to put weight as tolerated in a removable boot. They are typically unable to put full weight until the same 3 weeks period, but rehabilitation can be started as soon as soft tissues are in good conditions and pain is under control.

Summary:

Although full understanding and solution of every ankle fracture is not yet achieved, there has been significant improvement in the last few years with a clear trend into improving diagnosis, anatomical reduction and also into flexible fixation.

Cristian Ortiz, MD

SYNDESMOSIS EXPERT IMPLANTS

Code	Description
312-2000	Expert Knotless – Syndesmosis Flexible Fixation
314-2000	Expert Knotless Dual – Syndesmosis Double Flexible Fixation

SYNDESMOSIS EXPERT INSTRUMENTS

Code	Description
314-100	Syndesmosis Reduction Clamp
310-01-10	Expert Double Drill Guide
310-01-05	Ø1.0 / 3.8 mm K wire cannula
310-01-08	Ø3.8 x 180.0 mm Cannulated Drill Bit
310-01-08-S	Ø3.8 x 180.0 mm Drill Bit
310-01-07	Ø1.0 x 250.0 mm K wire
310-16-100	Ø1.6 x 80.0 mm K wire
172.17	Ø2.0 x 150.0 mm K wire

References:

- "State of the art on ankle fracture in Chile"; Foot and Ankle Clinics am (21) 367-369 2016. C.Ortiz, EWagner, PWagner
- Suture Button Versus Syndesmotic Screw for Syndesmosis Injuries: A Meta-analysis of Randomized Controlled Trials.
- Shimozono Y, Hurley ET, Myerson CL, Murawski CD, Kennedy JG. Am J Sports Med. 2019 Sep;47(11):2764-2771.
- A Systematic Review and Meta-Analysis on Treatment of Ankle Fractures With Syndesmotic Rupture: Suture-Button Fixation Versus Cortical Screw Fixation.
- McKenzie AC, Hesselholt KE, Larsen MS, Schmal H. J Foot Ankle Surg. 2019 Sep;58(5):946-953.
- Diagnosis and treatment of ankle syndesmosis injuries with associated interosseous membrane injury: a current concept review. Yu GS, Lin YB, Xiong GS, Xu HB, Liu YY. Int Orthop. 2019 Nov;43(11):2539-2547. Anatomic Ligament Repairs of Syndesmotic Injuries.
- Syndesmosis injuries at the ankle. Rammelt S, Manke E. Unfallchirurg. 2018 Sep;121(9):693-703.
- Diagnosis and treatment of tibiofibular syndesmosis lesions. Tourné Y, Molinier F, Andrieu M, Porta J, Barbier G. Orthop Traumatol Surg Res. 2019 Dec;105(8S):S275-S286.
- Acute and Chronic Syndesmotic Injury: The Authors' Approach to Treatment. Swords M, Brilhault J, Sands A. Foot Ankle Clin. 2018 Dec;23(4):625-637.
- Syndesmosis Stabilisation: Screws Versus Flexible Fixation. Solan MC, Davies MS, Sakellariou A. Foot Ankle Clin. 2017 Mar;22(1):35-63.
- Malreduction of syndesmosis injury associated with malleolar ankle fracture can be avoided using Weber's three indexes in the mortise view. Injury. 2017 Feb. Futamura K, et al
- Bone Joint J. 2016. Should syndesmotic screws be removed after surgical fixation of unstable ankle fractures?. A systematic review. Dingemans, Rammelt, et al
- A systematic review on dynamic versus static distal tibiofibular fixation. Injury. 2016 Dec;47(12):2627-2634. Inge SY(1) et al
- Biomechanical Comparison of 3 Current Ankle Syndesmosis Repair Techniques. Foot Ankle Int. 2017 Feb;38(2):200-207. Clanton TO(1,)
- Phisitkul P, Ebinger T, Goetz J, et al. Forceps reduction of the syndesmosis in rotational ankle fractures: a cadaveric study. J Bone Joint Surg Am 2012; 94(24):2256-61.
- Deltoid ligament repair vrs syndesmotic fixation in bimalleolar equivalent fracture. Jones, Nunley. J Orthop trauma; V 29, N 5, March 2015
- Miller AN, Carroll EA, Parker RJ, et al. Posterior malleolar stabilization of syndes-motic injuries is equivalent to screw fixation. Clin Orthop Relat Res 2010;468(4): 112935